Medicine Insights

Review

Imaging Phenotypes to Guide Intravenous Thrombolysis in Acute Ischemic Stroke: From Thrombus Characterization to Treatment Outcome Prediction

Haili Zhao[1] and Bingcang Huang[2,*]

[1] School of Gongli Hospital Medical Technology, University of Shanghai for Science and Technology, Shanghai, China
[2] Department of Radiology, Gongli Hospital of Shanghai Pudong New Area, Shanghai, China
* Correspondence: Bingcang Huang, Department of Radiology, Gongli Hospital of Shanghai Pudong New Area, Shanghai, China

Abstract: Intravenous thrombolysis (IVT) is an important reperfusion treatment for acute ischemic stroke (AIS), but variable treatment responses limit the ability of onset time alone to predict recanalization and tissue recovery. Identifying patients likely to benefit while minimizing hemorrhagic transformation remains challenging. Multimodal imaging has expanded pretreatment assessment beyond arterial occlusion to include thrombus characteristics, collateral circulation, and ischemic tissue status. Thrombus density, length, and permeability may help predict early recanalization, while computed tomography perfusion and magnetic resonance imaging support selection of some patients with unknown onset or beyond conventional treatment windows. However, recanalization does not necessarily ensure effective tissue reperfusion or favorable functional outcomes, and the independent predictive value of imaging markers for treatment benefit and hemorrhagic risk remains uncertain. Drawing on recent randomized controlled trials and imaging studies, this review examines associations between imaging phenotypes, thrombolytic response, hemorrhagic transformation, and long-term functional outcomes, with emphasis on thrombus characterization and ischemic tissue assessment. It also discusses the potential and limitations of radiomics and artificial intelligence for combined prediction. Future research should clarify relationships between imaging phenotypes and treatment effects and develop multicenter-validated benefit and risk prediction models to guide individualized IVT selection.

Keywords: acute ischemic stroke; intravenous thrombolysis; multimodal imaging; thrombus phenotype; radiomics

Received: 24 September 2026
Revised: 08 November 2026
Accepted: 19 November 2026
Published: 23 November 2026

Copyright: © 2026 by the authors. Submitted for possible open access publication under the terms and conditions of the Creative Commons Attribution (CC BY) license (https://creativecommons.org/licenses/by/4.0/).

1. Introduction

Intravenous thrombolysis (IVT) is an important reperfusion treatment for acute ischemic stroke (AIS). Its therapeutic efficacy depends not only on the time from symptom onset to treatment but also on thrombus characteristics, the site of arterial occlusion, and the status of ischemic brain tissue [1]. In clinical practice, some patients achieve early vascular recanalization after IVT but experience unfavorable functional outcomes because of established brain tissue injury or impaired microvascular perfusion. Conversely, others may retain salvageable brain tissue beyond the conventional treatment window owing to relatively preserved collateral circulation [2]. hese differences in treatment response indicate that, although time from symptom onset remains an important determinant of thrombolytic benefit, it is insufficient on its own to predict thrombus susceptibility to fibrinolysis or the potential for ischemic tissue recovery. The 2026 American Heart Association/American Stroke Association (AHA/ASA) guidelines support the use of alteplase or tenecteplase in eligible patients with AIS within 4.5 hours of symptom onset and provide further guidance on imaging-based selection of patients with unknown onset time or those presenting within extended treatment windows [3].

Neuroimaging provides important information for understanding individual differences in response to IVT. Noncontrast computed tomography (NCCT) enables the identification of early ischemic changes and certain imaging signs of thrombus, whereas computed tomography angiography (CTA) allows assessment of the site of arterial occlusion, thrombus extent, and collateral circulation. Computed tomography perfusion (CTP) provides estimates of the ischemic core and hypoperfused tissue by characterizing cerebral hemodynamic abnormalities. Diffusion-weighted imaging (DWI) and fluid-attenuated inversion recovery (FLAIR) sequences of magnetic resonance imaging (MRI) further support treatment selection in patients with unknown stroke onset. Randomized controlled trials, including WAKE-UP and EXTEND, have demonstrated that patients meeting specific MRI or perfusion imaging criteria may benefit from IVT despite an unknown onset time or presentation beyond the conventional treatment window [4-6].

However, individual imaging markers reflect different aspects of the underlying pathophysiology. Thrombus density, length, and permeability primarily provide information on thrombus structure and local blood flow characteristics, whereas collateral circulation and perfusion parameters more directly reflect the blood supply to ischemic brain tissue following arterial occlusion. A higher probability of vascular recanalization does not necessarily translate into favorable functional recovery. Accordingly, this review examines the clinical relevance of thrombus and ischemic tissue imaging phenotypes in the context of IVT. Drawing on recent randomized controlled trials and imaging-based prediction studies, we discuss the contributions and limitations of neuroimaging in patient selection, prediction of vascular recanalization, assessment of hemorrhagic risk, and evaluation of long-term functional outcomes.

2. Thrombus and Vascular Imaging Phenotypes Associated with Intravenous Thrombolysis Response

2.1. NCCT for Assessment of Early Ischemic Changes and Thrombus Density

NCCT remains the primary imaging modality for emergency assessment of AIS , mainly because it enables rapid exclusion of intracranial hemorrhage and detection of early ischemic changes in the brain parenchyma [7]. As regional cerebral blood flow decreases, ischemic tissue may progressively exhibit loss of gray and white matter differentiation, obscuration of the insular ribbon, and reduced parenchymal attenuation. The Alberta Stroke Program Early CT Score (ASPECTS) provides a semiquantitative assessment of early ischemic injury by evaluating ischemic changes within the middle cerebral artery territory [8]. However, ASPECTS primarily reflects visible ischemic abnormalities in predefined anatomical regions and does not directly quantify ischemic core volume or tissue salvageability. In patients eligible for IVT within the conventional treatment window, imaging assessment should prioritize the exclusion of hemorrhage and identification of extensive established ischemic injury without delaying treatment for additional imaging examinations [9].

Beyond parenchymal abnormalities, the hyperdense vessel sign (HVS) provides additional imaging information about thrombus characteristics [10]. Its appearance is related to the relative distribution of erythrocytes, hemoglobin, and other thrombus components, with erythrocyte-rich thrombi potentially exhibiting higher CT attenuation [11]. However, thrombus attenuation is also influenced by hematocrit, acquisition parameters, vessel diameter, and partial volume effects. Therefore, the presence of an HVS cannot be considered definitive evidence of a specific thrombus histological composition [11]. A 2024 systematic review and meta-analysis involving 12 studies reported an association between the HVS and successful recanalization following mechanical thrombectomy, but found no significant association with favorable functional outcomes or symptomatic intracranial hemorrhage [12]. These findings cannot be directly extrapolated to the predictive value of the HVS for IVT alone.

Early ischemic changes and the HVS on NCCT therefore provide distinct but complementary information. The former primarily reflects established ischemic tissue

injury, whereas the latter facilitates thrombus identification and may guide further vascular imaging. Although thrombus attenuation has potential value in predicting recanalization, current evidence does not support using the HVS alone to determine the likelihood of successful IVT. Its interpretation should account for the site of arterial occlusion and other relevant imaging characteristics.

2.2. CTA for Assessment of Thrombus Length, Burden, and Perviousness

CTA enables identification of the occlusion site, thrombus distribution, and vascular opacification proximal and distal to the occlusion, providing a basis for assessing the arterial obstruction targeted by IVT [13]. Compared with distal small vessel occlusions, proximal large vessel occlusions generally involve a greater thrombus burden and may be associated with more extensive downstream hypoperfusion. Thrombus length and the clot burden score (CBS) further characterize the extent of arterial obstruction, although neither directly reflects the histological composition of the thrombus [14]. Longer thrombi may limit the ability of fibrinolytic agents to act effectively throughout the thrombus, but the relationship between thrombus length and recanalization also depends on occlusion location, thrombus composition, and local hemodynamic conditions. Moreover, single-phase CTA may overestimate thrombus length because of insufficient contrast opacification distal to the occlusion, making thresholds derived from different studies difficult to compare directly [15].

Beyond thrombus length, thrombus perviousness provides information about the extent of contrast penetration into the thrombus. Previous studies have indirectly assessed perviousness by measuring the thrombus attenuation increase (TAI) between NCCT and CTA images. Santos et al. reported that greater thrombus perviousness was associated with vascular recanalization and favorable functional outcomes following treatment with intravenous recombinant tissue plasminogen activator [16]. Subsequent studies using dual-energy CT have investigated intrathrombus contrast distribution through iodine maps and normalized iodine concentration measurements, reporting associations between these parameters and recanalization and clinical outcomes after IVT [17].

The clinical relevance of thrombus perviousness lies in its ability to provide indirect information about intrathrombus structure and drug accessibility. However, the penetration of iodinated contrast agents does not necessarily reflect the actual distribution of alteplase or tenecteplase within the thrombus. Measurements of thrombus perviousness may also be affected by CTA acquisition timing, residual local blood flow, and image registration errors. Thrombus length, burden, and perviousness should therefore be interpreted as complementary imaging phenotypes rather than independent determinants of thrombolytic efficacy.

2.3. Collateral Circulation and Its Relationship to Tissue Perfusion

The extent of tissue injury following arterial occlusion depends not only on thrombus characteristics but also on the compensatory capacity of collateral circulation [18]. In anterior circulation large vessel occlusion, leptomeningeal collaterals can maintain a degree of distal blood flow through connections between adjacent arterial territories, thereby delaying ischemic core expansion. CTA allows assessment of collateral circulation based on the extent and degree of vascular opacification distal to the occlusion. However, single-phase CTA is sensitive to contrast arrival time and may misclassify delayed collateral filling as inadequate collateral supply [19, 20]. Multiphase CTA evaluates vascular opacification at successive time points and can help distinguish delayed collateral filling from genuinely poor collateral circulation.

The relationship between collateral circulation and IVT response is primarily mediated by its influence on downstream tissue status. Relatively preserved collateral supply may maintain salvageable brain tissue despite persistent arterial occlusion, while residual blood flow distal to the thrombus may also influence drug exposure at the occlusion site [21, 22]. Nevertheless, favorable collateral opacification does not necessarily indicate preserved tissue oxygen metabolism or guarantee adequate microvascular reperfusion following recanalization. Collateral circulation is therefore more

appropriately considered an adjunctive indicator of tissue injury and functional prognosis rather than an independent criterion for IVT eligibility [23].

The interplay between thrombus length, thrombus burden, and collateral circulation may also explain differences in treatment outcomes among patients with occlusions at similar anatomical locations. Even when thrombus extent is comparable, differences in collateral supply may result in substantially different ischemic core volumes and distributions of hypoperfused tissue. Thrombus imaging phenotypes can therefore characterize vascular conditions relevant to recanalization, but determining whether IVT is likely to translate into meaningful neurological benefit requires further assessment of ischemic brain tissue status.

3. Ischemic Tissue Imaging Phenotypes and Assessment of Intravenous Thrombolysis Benefit

3.1. CTP for Assessment of the Ischemic Core and Penumbra

The extent of brain tissue injury following arterial occlusion varies considerably among patients. Some develop extensive infarction early after ischemic onset, whereas others retain salvageable brain tissue despite prolonged arterial occlusion [19]. Consequently, symptom onset time and occlusion location alone are insufficient to determine the potential benefit of IVT . CTP dynamically tracks contrast passage through brain tissue to derive parameters including cerebral blood flow (CBF), cerebral blood volume (CBV), and time to maximum of the residue function (Tmax), providing quantitative estimates of the ischemic core and hypoperfused tissue [24].

In perfusion analysis protocols validated in clinical trials, tissue with a relative CBF below 30% of that in a reference region is commonly used to estimate the ischemic core, whereas regions with Tmax greater than 6 s are used to identify tissue with substantial perfusion delay [25]. The volumetric difference between these regions can be used to calculate perfusion mismatch and help identify potentially salvageable tissue. Trials including EXTEND used perfusion mismatch to select patients presenting within extended treatment windows and demonstrated that selected patients could benefit from IVT [5]. However, perfusion delay does not necessarily indicate ischemic penumbra, and reduced CBF does not invariably imply irreversible tissue injury. In particular, CTP may overestimate the ischemic core in patients with severe hypoperfusion imaged very early after stroke onset, a phenomenon commonly referred to as the ghost infarct core [26]. A 2023 systematic review further reported that CTP core overestimation is influenced by imaging timing, hemodynamic conditions, and postprocessing methods [27].

The principal value of CTP lies not in precisely delineating the boundaries of irreversible tissue injury, but in identifying patients who meet established imaging criteria for treatment selection. Differences in perfusion models, reference regions, and thresholds across software platforms may introduce variability in core and hypoperfusion estimates. Delayed collateral filling and chronic arterial stenosis may further complicate interpretation. CTP findings should therefore be evaluated alongside early ischemic changes on NCCT, the occlusion site on CTA, and the clinical presentation. Treatment decisions should not rely solely on a single automated perfusion analysis, particularly when this could exclude patients who might benefit from reperfusion therapy.

3.2. MRI for Assessment of Ischemic Tissue Injury and the Tissue-Based Treatment Window

MRI provides information complementary to CTP through sequences with different sensitivities to ischemic tissue changes. DWI is highly sensitive to restricted water diffusion associated with acute ischemia, whereas signal abnormalities on FLAIR generally become more conspicuous as tissue edema and ischemic injury evolve [28]. The presence of a DWI hyperintense lesion without corresponding marked FLAIR hyperintensity, known as diffusion-weighted imaging and fluid-attenuated inversion recovery (DWI-FLAIR) mismatch, can help estimate the relative age of ischemic lesions in selected patients with unknown stroke onset. Unlike perfusion mismatch, which

primarily reflects abnormalities in tissue blood supply, DWI-FLAIR mismatch identifies ischemic lesions that may be at a relatively early stage of evolution [29].

The WAKE-UP trial used DWI-FLAIR mismatch to select patients with AIS of unknown onset. At 90 days, 53.3% of patients receiving alteplase achieved a modified Rankin Scale (mRS) score of 0 or 1, compared with 41.8% in the placebo group. These findings provided randomized controlled trial evidence supporting MRI-guided IVT in selected patients with wake-up stroke or unknown symptom onset [4]. Nevertheless, DWI-FLAIR mismatch does not directly quantify the ischemic penumbra, and its interpretation is influenced by lesion location, signal intensity, and acquisition parameters. FLAIR signal abnormalities may be less conspicuous in patients with small ischemic lesions or posterior circulation stroke, potentially reducing the consistency of imaging classification.

MRI-based tissue timing and CTP-derived perfusion mismatch therefore represent distinct approaches to treatment selection. The former estimates the relative timing of ischemic injury from the evolution of lesion signal characteristics, whereas the latter assesses potentially salvageable tissue based on regional perfusion abnormalities. Both approaches can extend treatment selection beyond conventional time-based criteria in appropriately selected patients. However, their target populations and eligibility criteria differ, and the two methods should not be considered interchangeable without further validation (As shown in Table 1).

Table 1. Clinical Relevance and Limitations of Imaging Phenotypes in Intravenous Thrombolysis for Acute Ischemic Stroke

magin g modali ty	**Imagin g phenot ype**	**Representativ e parameters**	**Clinical relevance to IVT**	**Evidence limitations**	**Ref eren ces**
NCCT	Early ischemi c change s	ASPECTS; loss of gray–white matter differentiation ; parenchymal hypoattenuati on	Identifies early ischemic injury and supports baseline assessment of tissue damage and treatment safety.	ASPECTS does not directly quantify infarct core volume; assessment varies with imaging time and interobserver interpretation.	[3, 7-9]
NCCT	Hyperd ense vessel sign	HVS; thrombus attenuation (HU)	Indicates the presence of thrombus and provides indirect information on thrombus characteristics relevant to recanalization.	Influenced by hematocrit, acquisition parameters, and partial-volume effects; limited evidence for independently predicting IVT outcomes.	[11, 12]
CTA	Throm bus extent and burden	Thrombus length; CBS; occlusion site	Characterizes the extent and distribution of arterial occlusion and may inform early recanalization assessment.	Single-phase CTA may overestimate thrombus length; associations vary by occlusion site and measurement technique.	[14]
CTA / DECT	Throm bus perviou sness	TAI; CTA index; iodine concentration	Reflects contrast penetration into the thrombus; greater perviousness has been associated with recanalization and favorable functional outcomes after IVT.	Contrast penetration does not directly represent thrombolytic drug delivery; measurements are sensitive to acquisition timing, image registration, and local blood flow.	[16, 17]

CTA / multiphase CTA	Collateral circulation	Collateral score; distal vessel filling; filling delay	Characterizes collateral perfusion and provides information on infarct progression, tissue viability, and functional prognosis.	Single-phase CTA may underestimate delayed collateral filling; collateral visualization does not directly establish tissue viability.	[18, 19, 21, 23]
CTP	Ischemic core	Relative CBF; estimated core volume	Estimates the extent of severely hypoperfused tissue and contributes to assessment of baseline ischemic injury.	Estimates depend on software-specific thresholds and may overestimate irreversible injury, particularly in the hyperacute phase.	[24, 27]
CTP / MR perfusion	Perfusion mismatch	Tmax; mismatch volume; mismatch ratio	Identifies selected patients with potentially salvageable tissue beyond the conventional IVT time window, supported by randomized trial evidence.	Perfusion delay does not invariably indicate ischemic penumbra; thresholds and eligibility criteria are not universally transferable.	[30]

4. Imaging-Guided Intravenous Thrombolysis Strategies

4.1. Treatment Selection within the Conventional Time Window and in Patients with Unknown Stroke Onset

For patients with AIS presenting within 4.5 hours of symptom onset, disabling neurological deficits, and no contraindications to treatment, prompt initiation of IVT remains a priority [31]. The 2026 American Heart Association/American Stroke Association (AHA/ASA) guidelines support the use of alteplase at 0.9 mg/kg or tenecteplase at 0.25 mg/kg and emphasize that treatment in eligible patients should not be delayed to obtain additional CTA, CTP, or MRI [3]. Within this time window, NCCT is primarily used to exclude intracranial hemorrhage and identify extensive established ischemic injury, while CTA can simultaneously detect large vessel occlusion and inform decisions regarding mechanical thrombectomy. Although thrombus length, density, and collateral circulation may influence the probability of recanalization, current evidence is insufficient to support selecting a specific thrombolytic agent based on these imaging characteristics alone.

Imaging assessment plays a greater role in patients with unknown stroke onset or those presenting beyond the conventional treatment window. The WAKE-UP trial selected patients based on DWI-FLAIR mismatch, whereas the EXTEND trial used CTP or MRI perfusion mismatch to identify eligible patients presenting 4.5 to 9 hours after stroke onset or with wake-up stroke meeting specified timing criteria. In EXTEND, 35.4% of patients receiving alteplase achieved a modified Rankin Scale (mRS) score of 0 or 1 at 90 days, compared with 29.5% in the placebo group, although the risk of symptomatic intracranial hemorrhage was also increased [5]. A 2019 individual patient data meta-analysis of randomized trials involving extended treatment windows further supported the potential benefit of IVT in patients selected using perfusion imaging [30].

These studies have advanced IVT selection beyond symptom onset time alone by incorporating assessments of tissue status. However, imaging cannot entirely replace temporal information. As ischemia persists, cerebral microvascular injury and blood-brain barrier dysfunction may progress, potentially increasing the risk of treatment-related hemorrhage even when some degree of perfusion mismatch remains. Imaging-based selection should therefore follow clinically validated eligibility criteria, and perfusion thresholds established in individual trials should not be applied indiscriminately to all patients with AIS.

4.2. Recent Clinical Evidence for Intravenous Thrombolysis in Extended Treatment Windows

Recent trials have further investigated imaging-guided IVT in patients presenting 4.5 to 24 hours after stroke onset. The 2024 TRACE III trial enrolled 516 patients with anterior circulation large vessel occlusion, salvageable tissue identified by perfusion imaging, and no access to endovascular thrombectomy. At 90 days, 33.0% of patients receiving tenecteplase achieved an mRS score of 0 or 1, compared with 24.2% receiving standard medical treatment, although symptomatic intracranial hemorrhage occurred more frequently in the tenecteplase group [32]. In contrast, the TIMELESS trial, which also used perfusion imaging to select patients within 4.5 to 24 hours, found no significant improvement in the primary functional outcome with tenecteplase. The high proportion of patients undergoing mechanical thrombectomy in TIMELESS may have influenced the assessment of the additional benefit of IVT [33].

Subsequent trials have broadened the populations considered for imaging-guided treatment. The 2025 HOPE trial enrolled 372 patients presenting 4.5 to 24 hours after stroke onset who had salvageable tissue identified by CTP and were not scheduled for immediate mechanical thrombectomy. Alteplase increased the proportion of patients achieving a favorable functional outcome without substantial disability at 90 days, although it was also associated with an increased risk of symptomatic intracranial hemorrhage [34]. The 2026 OPTION trial focused on patients with AIS without large vessel occlusion and enrolled 566 participants. At 90 days, 43.6% of patients receiving tenecteplase achieved an mRS score of 0 or 1, compared with 34.2% in the standard medical treatment group [35]. Together, these findings suggest that the potential clinical value of imaging-guided selection may extend beyond proximal large vessel occlusion to different occlusion patterns and thrombolytic agents.

However, differences across trials in arterial occlusion patterns, imaging mismatch criteria, access to mechanical thrombectomy, and treatment protocols may have contributed to variations in clinical outcomes. Importantly, demonstrating the efficacy of a treatment in an imaging-selected population is distinct from establishing that an individual imaging marker predicts the magnitude of additional benefit from that treatment. Although current trials support the clinical utility of selected imaging-based treatment strategies, direct evidence remains insufficient to determine whether specific thrombus or tissue imaging phenotypes can guide the choice of thrombolytic agent.

5. Imaging Phenotypes for Predicting the Efficacy and Safety of Intravenous Thrombolysis

5.1. Vascular Recanalization, Tissue Reperfusion, and Functional Outcomes

Early vascular recanalization is an important measure of IVT efficacy, but does not necessarily indicate adequate reperfusion of ischemic brain tissue. Some patients experience unfavorable functional outcomes despite successful large vessel recanalization because of extensive established tissue injury, impaired distal microvascular perfusion, or secondary hemorrhage [36]. Thrombus length, density, and perviousness are primarily associated with vascular recanalization, whereas pretreatment ischemic core volume, collateral circulation, and lesion location further influence tissue recovery following restoration of blood flow. Therefore, vascular recanalization alone cannot fully capture the functional benefit of IVT.

Long-term functional outcomes are commonly assessed using the modified Rankin Scale (mRS) at 90 days, which reflects the overall degree of disability. However, these outcomes are also influenced by baseline neurological deficits, lesion location, and posttreatment complications [37].Even in patients with comparable ischemic core volumes, differences in the involvement of motor, language, or other functionally critical brain regions may result in substantially different neurological impairments. Imaging-derived volume measurements therefore cannot fully replace assessments of lesion distribution and clinical functional status.

Imaging-based prediction requires clear distinctions between clinical endpoints. Early vascular recanalization reflects arterial patency following fibrinolytic treatment,

whereas tissue reperfusion indicates whether blood supply to ischemic regions has improved. Long-term functional outcomes incorporate the consequences of brain tissue injury and subsequent recovery. Distinguishing these endpoints is essential for determining whether an imaging marker is useful for predicting thrombus dissolution, tissue salvage, or eventual functional recovery.

5.2. Hemorrhagic Transformation and Imaging-Based Safety Assessment

Hemorrhagic transformation (HT) is an important safety outcome following reperfusion therapy for AIS, particularly when symptomatic intracranial hemorrhage (sICH) leads to neurological deterioration and unfavorable outcomes. Prolonged severe ischemia can damage the cerebral microvascular endothelium and disrupt blood-brain barrier integrity, increasing vascular susceptibility to extravasation of blood components following reperfusion [38]. Patients with extensive ischemic injury before treatment may therefore face a greater risk of hemorrhage. Early hypoattenuation on NCCT, a large ischemic core estimated by CTP, and extensive diffusion abnormalities on MRI can provide information about the severity of tissue injury. However, none of these findings can independently determine whether sICH will occur [39, 40].

Imaging-based safety prediction also requires consideration of clinical risk factors. A 2024 systematic review and meta-analysis examining risk prediction for HT after intravenous alteplase identified associations with baseline National Institutes of Health Stroke Scale (NIHSS) scores, blood glucose levels, atrial fibrillation, larger infarct extent, and early ischemic changes. However, most prediction models included in the review were judged to have a risk of bias [41]. Moreover, HT and sICH differ in their definitions and clinical severity, and radiologically detected hemorrhagic changes should not be equated with clinically symptomatic intracranial hemorrhage.

Safety assessment before IVT should therefore extend beyond ischemic core volume to incorporate the extent and location of tissue injury alongside baseline clinical characteristics. This is particularly important in patients presenting within extended treatment windows, as the presence of salvageable tissue on imaging does not imply that hemorrhagic risk is negligible. Further research is needed to establish which imaging features provide independent predictive information beyond conventional clinical risk factors and thereby improve the assessment of treatment benefit and safety.

5.3. Radiomics and Artificial Intelligence for Predicting Thrombolytic Outcomes

Conventional imaging markers primarily characterize thrombus attenuation, morphology, and the extent of ischemic tissue injury, but provide limited information about intrathrombus heterogeneity and more complex imaging patterns. Radiomics enables the extraction of intensity, texture, and shape features from CT and MRI images, offering additional approaches to investigating thrombus structural heterogeneity and its relationship to treatment response [42]. A 2025 study of dual-energy CT thrombus radiomics explored its potential for predicting functional outcomes after IVT in patients with AIS, providing preliminary evidence for quantitative thrombus assessment beyond conventional attenuation measurements [43]. However, imaging texture features cannot be directly attributed to specific histological thrombus components, and their measurements remain sensitive to acquisition parameters, image segmentation, and feature extraction methods.

Machine learning approaches can further integrate thrombus characteristics, perfusion parameters, and clinical variables to develop predictive models for vascular recanalization, hemorrhagic transformation, and functional outcomes. A 2026 study involving patients with anterior circulation AIS treated with IVT investigated the use of radiomics combined with machine learning to predict hemorrhagic transformation [44]. Nevertheless, high model discrimination does not necessarily translate into clinical utility. Some models are limited by small training datasets, excessive numbers of imaging features, and a lack of independent external validation, potentially reducing their predictive performance across imaging platforms and patient populations.

Future imaging-based prediction models should prioritize clinical added value rather than improvements in the area under the receiver operating characteristic curve (AUC) alone. Models intended to support pretreatment decisions should include only information available before thrombolytic administration and undergo independent validation of their predictive performance and calibration. More importantly, prognostic models developed exclusively in patients who received IVT cannot establish whether they can guide the decision to administer thrombolysis. Determining whether imaging phenotypes can meaningfully improve patient selection requires further evaluation of their relationship with treatment effects in studies that include appropriate comparator groups (As shown in Figure 1).

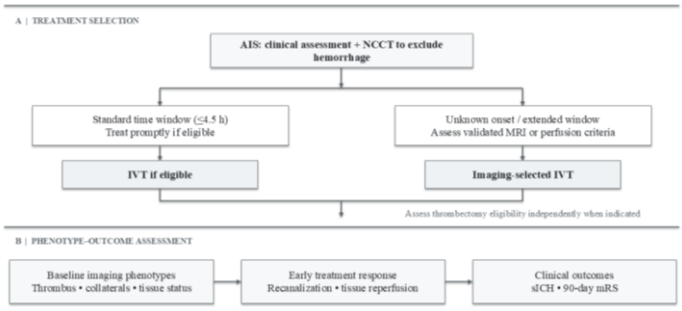

Figure 1. Imaging Phenotype-Guided Framework for Intravenous Thrombolysis Selection and Clinical Outcome Assessment. (A) Treatment Selection for Patients with AIS Based on Clinical Assessment and NCCT, Including IVT within the Standard Treatment Window and MRI- or Perfusion Imaging-Based Selection for Patients with Unknown Onset or an Extended Treatment Window, with Thrombectomy Eligibility Assessed Independently. (B) Assessment Framework Linking Baseline Thrombus Characteristics, Collateral Circulation, and Ischemic Tissue Status to Early Recanalization, Tissue Reperfusion, and Clinical Outcomes, Including Symptomatic Intracranial Hemorrhage (sICH) and the Modified Rankin Scale (mRS) Score at 90 Days.

6. Conclusions and Future Perspectives

The role of neuroimaging in IVT for AIS has expanded from the early exclusion of intracranial hemorrhage and detection of ischemic lesions to the characterization of thrombus features, assessment of tissue salvageability, and prediction of treatment outcomes. NCCT and CTA provide information on thrombus attenuation, occlusion location, thrombus length, and perviousness, whereas CTP and MRI further characterize ischemic tissue injury and perfusion status. However, these imaging markers reflect different pathophysiological processes, and associations between thrombus characteristics and early vascular recanalization do not necessarily indicate an ability to predict long-term functional benefit. Imaging assessment for IVT should therefore distinguish vascular recanalization, tissue reperfusion, and functional outcomes rather than relying on a single parameter to evaluate overall treatment efficacy.

Randomized controlled trials, including WAKE-UP, EXTEND, and subsequent studies involving extended treatment windows, have demonstrated that selected patients meeting specific MRI or perfusion imaging criteria can benefit from IVT. Nevertheless, differences in arterial occlusion patterns, subsequent endovascular treatment, and hemorrhagic risk across trials indicate that the clinical value of imaging-guided selection remains dependent on treatment context. Future studies should further investigate the relationships between thrombus and tissue imaging phenotypes and responses to thrombolytic agents, while distinguishing general prognostic markers from those capable of identifying additional treatment benefit.

Radiomics and artificial intelligence offer new approaches to integrating multimodal imaging information, but their clinical translation requires improvements in imaging standardization, external model validation, and interpretability of predictions. Future prospective multicenter studies should evaluate the independent contributions of thrombus characteristics, ischemic tissue status, and clinical variables to recanalization,

hemorrhagic risk, and functional outcomes, while determining whether predictive models improve treatment decisions in clinical practice. The primary goal of imaging-guided IVT is not to increase the number of imaging examinations or predictive parameters, but to identify brain tissue that may benefit from reperfusion using reliable imaging evidence and to improve individualized assessment of treatment benefits and risks without unnecessary delays in treatment.

References

1. T. C. Tao, T. Liu, T. Cui, J. Liu, Z. Li, Y. Ren, et al., "Early Tirofiban Infusion after Intravenous Thrombolysis for Stroke," *N Engl J Med*, vol. 393, no. 12, pp. 1191–1201, 2025.
2. L. Schlemm, T. B. Braemswig, F. Boutitie, J. Vynckier, M. Jensen, I. Galinovic, et al., "Cerebral Microbleeds and Treatment Effect of Intravenous Thrombolysis in Acute Stroke: An Analysis of the WAKE-UP Randomized Clinical Trial," *Neurology*, vol. 98, no. 3, pp. e302–e314, 2022.
3. S. Prabhakaran, N. R. Gonzalez, K. S. Zachrison, O. Adeoye, A. W. Alexandrov, S. A. Ansari, et al., "2026 Guideline for the Early Management of Patients With Acute Ischemic Stroke: A Guideline From the American Heart Association/American Stroke Association," *Stroke*, vol. 57, no. 8, pp. e316–e436, 2026.
4. G. Thomalla, C. Z. Simonsen, F. Boutitie, G. Andersen, Y. Berthezene, B. Cheng, et al., "MRI-Guided Thrombolysis for Stroke with Unknown Time of Onset," *N Engl J Med*, vol. 379, no. 7, pp. 611–622, 2018.
5. H. Ma, B. C. V. Campbell, M. W. Parsons, L. Churilov, C. R. Levi, C. Hsu, et al., "Thrombolysis Guided by Perfusion Imaging up to 9 Hours after Onset of Stroke," *N Engl J Med*, vol. 380, no. 19, pp. 1795–1803, 2019.
6. G. Thomalla, F. Boutitie, H. Ma, M. Koga, P. Ringleb, L. H. Schwamm, et al., "Intravenous alteplase for stroke with unknown time of onset guided by advanced imaging: systematic review and meta-analysis of individual patient data," *Lancet*, vol. 396, no. 10262, pp. 1574–1584, 2020.
7. Y. Zhou, Y. Jing, J. Ospel, M. Goyal, R. McDonough, X. Yue, et al., "CT Hyperdense Artery Sign and the Effect of Alteplase in Endovascular Thrombectomy after Acute Stroke," *Radiology*, vol. 305, no. 2, pp. 410–418, 2022.
8. H. Kuang, B. K. Menon, S. I. Sohn, and W. Qiu, "EIS-Net: Segmenting early infarct and scoring ASPECTS simultaneously on non-contrast CT of patients with acute ischemic stroke," *Med Image Anal*, vol. 70, p. 101984, 2021.
9. H. Kuang, M. Najm, D. Chakraborty, N. Maraj, S. I. Sohn, M. Goyal, et al., "Automated ASPECTS on Noncontrast CT Scans in Patients with Acute Ischemic Stroke Using Machine Learning," *AJNR Am J Neuroradiol*, vol. 40, no. 1, pp. 33–38, 2019.
10. T. Miki, T. Miyoshi, K. Suruga, K. Ichikawa, H. Otsuka, H. Toda, et al., "Triglyceride to HDL-cholesterol ratio is a predictor of future coronary events: a possible role of high-risk coronary plaques detected by coronary CT angiography," *European Heart Journal*, vol. 41, Suppl. 2, 2020.
11. J. Kosyakovsky, C. P. Rossitto, J. P. Antonios, D. Renedo, C. J. Stapleton, L. H. Sansing, et al., "Clot Composition and Ischemic Stroke Etiology: A Contemporary Narrative Review," *J Clin Med*, vol. 14, no. 17, 2025.
12. K. Gharaibeh, N. Aladamat, M. Samara, A. T. Mierzwa, A. Ali, S. Zaidi, et al., "Hyperdense sign as a predictor for successful recanalization and clinical outcome in acute ischemic stroke: A systematic review and meta-analysis," *Interv Neuroradiol*, vol. 32, no. 4, pp. 1586–1593, 2026.
13. M. Berndt, F. Mück, C. Maegerlein, S. Wunderlich, C. Zimmer, S. Wirth, et al., "Introduction of CTA-index as Simplified Measuring Method for Thrombus Perviousness," *Clin Neuroradiol*, vol. 31, no. 3, pp. 773–781, 2021.
14. I. Derraz, M. Pou, J. Labreuche, L. Legrand, S. Soize, M. Tisserand, et al., "Clot Burden Score and Collateral Status and Their Impact on Functional Outcome in Acute Ischemic Stroke," *AJNR Am J Neuroradiol*, vol. 42, no. 1, pp. 42–48, 2021.
15. K. Yeung, J. P. Eiberg, A. Collet-Billon, B. V. Sandholt, M. L. Jessen, H. H. Sillesen, et al., "3-D Contrast-Enhanced Fusion Ultrasound for Accurate Volume Assessment of Vessel Lumen and Plaque in Carotid Artery Disease as Compared With Computed Tomography Angiography," *Ultrasound Med Biol*, vol. 50, no. 3, pp. 399–406, 2024.
16. E. M. Santos, J. W. Dankbaar, K. M. Treurniet, A. D. Horsch, Y. B. Roos, L. J. Kappelle, et al., "Permeable Thrombi Are Associated With Higher Intravenous Recombinant Tissue-Type Plasminogen Activator Treatment Success in Patients With Acute Ischemic Stroke," *Stroke*, vol. 47, no. 8, pp. 2058–2065, 2016.
17. Y. Dai, H. Xu, X. Fang, X. Xiong, Z. Song, S. Hu, et al., "Dual-energy CT in assessment of thrombus perviousness and its application in predicting outcomes after intravenous thrombolysis in acute ischemic stroke," *Eur J Radiol*, vol. 164, p. 110861, 2023.
18. T. D. Faizy, M. Mlynash, R. Kabiri, S. Christensen, G. Kuraitis, L. Meyer, et al., "Favourable arterial, tissue-level and venous collaterals correlate with early neurological improvement after successful thrombectomy treatment of acute ischaemic stroke," *J Neurol Neurosurg Psychiatry*, 2022.
19. H. A. Salim, D. A. Lakhani, J. Mei, M. Koneru, A. Balar, M. Hoseinyazdi, et al., "Composite arterial and venous collateral score on single-phase CTA predicts 90-day outcomes in anterior circulation large-vessel occlusion stroke," *J Neurointerv Surg*, vol. 18, no. 8, pp. 1749–1756, 2026.
20. K. C. Arthur, S. Huang, J. C. Gudenkauf, A. Mohseni, R. Wang, A. Aslan, et al., "Assessing the Relationship between LAMS and CT Perfusion Parameters in Acute Ischemic Stroke Secondary to Large Vessel Occlusion," *J Clin Med*, vol. 12, no. 10, 2023.

21. D. A. Lakhani, A. B. Balar, M. Koneru, M. Hoseinyazdi, N. Hyson, A. Cho, et al., "Pretreatment CT perfusion collateral parameters correlate with penumbra salvage in middle cerebral artery occlusion," *J Neuroimaging*, vol. 34, no. 1, pp. 44–49, 2024.
22. D. A. Lakhani, A. B. Balar, M. Koneru, S. Wen, B. B. Ozkara, R. Wang, et al., "CT perfusion based rCBF <38% volume is independently and negatively associated with digital subtraction angiography collateral score in anterior circulation large vessel occlusions," *Neuroradiol J*, vol. 37, no. 4, pp. 462–467, 2024.
23. D. A. Lakhani, A. B. Balar, M. Koneru, S. Wen, B. B. Ozkara, J. Caplan, et al., "Perfusion-Based Relative Cerebral Blood Volume Is Associated With Functional Dependence in Large-Vessel Occlusion Ischemic Stroke," *J Am Heart Assoc*, vol. 13, no. 23, p. e034242, 2024.
24. H. Kuang, W. Qiu, A. M. Boers, S. Brown, K. Muir, C. Majoie, et al., "Computed Tomography Perfusion-Based Machine Learning Model Better Predicts Follow-Up Infarction in Patients With Acute Ischemic Stroke," *Stroke*, vol. 52, no. 1, pp. 223–231, 2021.
25. X. Hao, C. Zhang, C. Yang, X. Zhao, Y. Zhou, and J. Wang, "Introducing an index on prediction of post-revascularization cerebral infarction using preoperative CT perfusion parameters in moyamoya disease," *Insights Imaging*, vol. 16, no. 1, p. 2, 2025.
26. G. Furlanis, E. Ricci, M. Ajčević, F. Spigariol, E. Vincis, G. Prandin, et al., "Effectiveness of CT perfusion in posterior circulation stroke: evaluation of perfusion abnormalities and associated clinical signs," *J Neurol*, vol. 272, no. 3, p. 225, 2025.
27. A. A. Ballout, S. Y. Oh, B. Huang, A. Patsalides, and R. B. Libman, "Ghost infarct core: A systematic review of the frequency, magnitude, and variables of CT perfusion overestimation," *J Neuroimaging*, vol. 33, no. 5, pp. 716–724, 2023.
28. J. Xiao, R. A. Poblete, A. Lerner, P. L. Nguyen, J. W. Song, N. Sanossian, et al., "MRI in the Evaluation of Cryptogenic Stroke and Embolic Stroke of Undetermined Source," *Radiology*, vol. 311, no. 1, p. e231934, 2024.
29. R. W. Regenhardt, M. Bretzner, M. C. Zanon Zotin, A. K. Bonkhoff, M. R. Etherton, S. Hong, et al., "Radiomic signature of DWI-FLAIR mismatch in large vessel occlusion stroke," *J Neuroimaging*, vol. 32, no. 1, pp. 63–67, 2022.
30. B. C. V. Campbell, H. Ma, P. A. Ringleb, M. W. Parsons, L. Churilov, M. Bendszus, et al., "Extending thrombolysis to 4·5-9 h and wake-up stroke using perfusion imaging: a systematic review and meta-analysis of individual patient data," *Lancet*, vol. 394, no. 10193, pp. 139–147, 2019.
31. A. Ahmadabad R. Ashayeri, K. Sobchuk, S. K. Cheema, P. N. Sylaja, M. Almekhlafi, A. Deshmukh, et al., "Risk of Early Recurrent Stroke and Thrombotic Events After Reperfusion Therapy in Acute Ischemic Stroke: A Meta-Analysis," *Stroke*, vol. 57, no. 1, pp. 77–88, 2026.
32. Y. Xiong, B. C. V. Campbell, L. H. Schwamm, X. Meng, A. Jin, M. W. Parsons, et al., "Tenecteplase for Ischemic Stroke at 4.5 to 24 Hours without Thrombectomy," *N Engl J Med*, vol. 391, no. 3, pp. 203–212, 2024.
33. G. W. Albers, M. Jumaa, B. Purdon, S. F. Zaidi, C. Streib, A. Shuaib, et al., "Tenecteplase for Stroke at 4.5 to 24 Hours with Perfusion-Imaging Selection," *N Engl J Med*, vol. 390, no. 8, pp. 701–711, 2024.
34. Y. Zhou, Y. He, B. C. V. Campbell, D. S. Liebeskind, C. Yuan, H. Chen, et al., "Alteplase for Acute Ischemic Stroke at 4.5 to 24 Hours: The HOPE Randomized Clinical Trial," *JAMA*, vol. 334, no. 9, pp. 788–797, 2025.
35. G. Ma, R. Mo, Y. Zuo, Q. Ma, G. Zhao, X. Yao, et al., "Tenecteplase for Acute Non-Large Vessel Occlusion 4.5 to 24 Hours After Ischemic Stroke: The OPTION Randomized Clinical Trial," *JAMA*, vol. 335, no. 13, pp. 1137–1147, 2026.
36. Y. Peng, H. Sun, F. Xu, H. Ye, Y. Wang, X. Zhou, et al., "Activation of BDNF-TrkB-PI3K-AKT signaling pathway by Tong-Qiao-Huo-Xue Decoction facilitates nerve regeneration and mitigates cerebral ischemia-reperfusion injury," *Phytomedicine*, vol. 145, p. 156966, 2025.
37. S. Rudilosso, X. Urra, S. Amaro, L. Llull, A. Renú, C. Laredo, et al., "Timing and Relevance of Clinical Improvement After Mechanical Thrombectomy in Patients With Acute Ischemic Stroke," *Stroke*, vol. 50, no. 6, pp. 1467–1472, 2019.
38. G. Yu, Y. J. Kim, S. B. Jeon, and W. Y. Kim, "Thromboelastography for prediction of hemorrhagic transformation in patients with acute ischemic stroke," *Am J Emerg Med*, vol. 38, no. 9, pp. 1772–1777, 2020.
39. C. Csutak, D. Ursu, A. Lebovici, M. Lenghel, A. Roman, C. Schiau, et al., "CT Texture Analysis of Acute Ischemic Stroke: Prediction of Hemorrhagic Transformation After Thrombolysis," *Brain Sci*, vol. 16, no. 6, 2026.
40. S. Massicotte, S. Vatanpour, C. Doolan, J. Zhang, A. Ganesh, P. M. C. Choi, et al., "Intracranial Hemorrhage Patterns and Outcomes in Minor Stroke: Analysis of the TEMPO-2 Trial," *Stroke*, vol. 57, no. 6, pp. 1526–1534, 2026.
41. K. Zhong, X. An, Y. Kong, and Z. Chen, "Predictive model for the risk of hemorrhagic transformation after rt-PA intravenous thrombolysis in patients with acute ischemic stroke: A systematic review and meta-analysis," *Clin Neurol Neurosurg*, vol. 239, p. 108225, 2024.
42. L. Jiang, Y. Zhou, Q. Xu, H. Huang, C. Li, F. Shi, et al., "Spatial radiomics-based interpretable multimodal machine learning model enhances outcomes prediction for minor stroke: A multicenter cohort study," *J Adv Res*, vol. 87, pp. 813–823, 2026.
43. Y. Ma, Y. Zhao, Y. Dai, Z. Song, J. Yang, C. Hu, et al., "Dual-Energy CT-Based Thrombus Radiomics Can Predict Functional Outcome of Intravenous Thrombolysis in Acute Ischemic Stroke," *Transl Stroke Res*, vol. 16, no. 5, pp. 1733–1744, 2025.
44. H. Shao, F. Li, X. Cai, W. Zhou, L. Ma, and C. Geng, "Prediction of hemorrhagic transformation after intravenous thrombolysis in acute anterior circulation ischemic stroke through radiomics-based machine learning models," *Eur J Med Res*, vol. 2026.

Disclaimer/Publisher's Note: The statements, opinions and data contained in all publications are solely those of the individual author(s) and contributor(s) and not of Publisher and/or the editor(s). Publisher and/or the editor(s) disclaim responsibility for any injury to people or property resulting from any ideas, methods, instructions or products referred to in the content.